

Pulmonary TB – X-ray changes

Richard Hughes

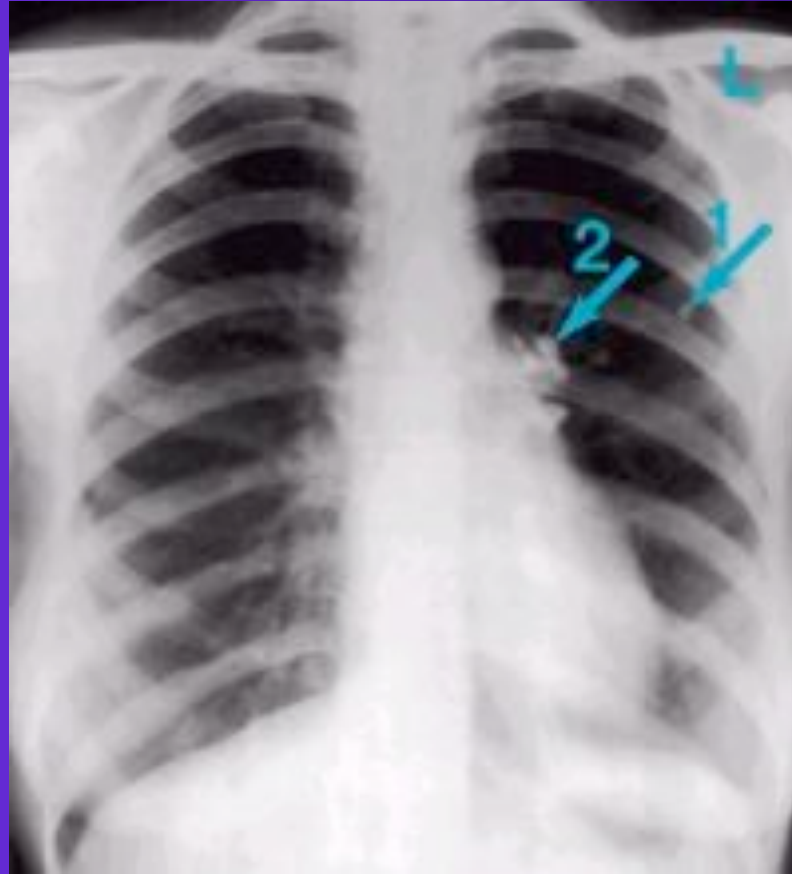
Primary Infection

- ◆ Hilar lymphadenopathy
- ◆ Pleural effusion
- ◆ Pulmonary infiltrates
- ◆ R middle lobe collapse (Brock's syndrome)
- ◆ Subsequent calcified lesion (Gohn focus)

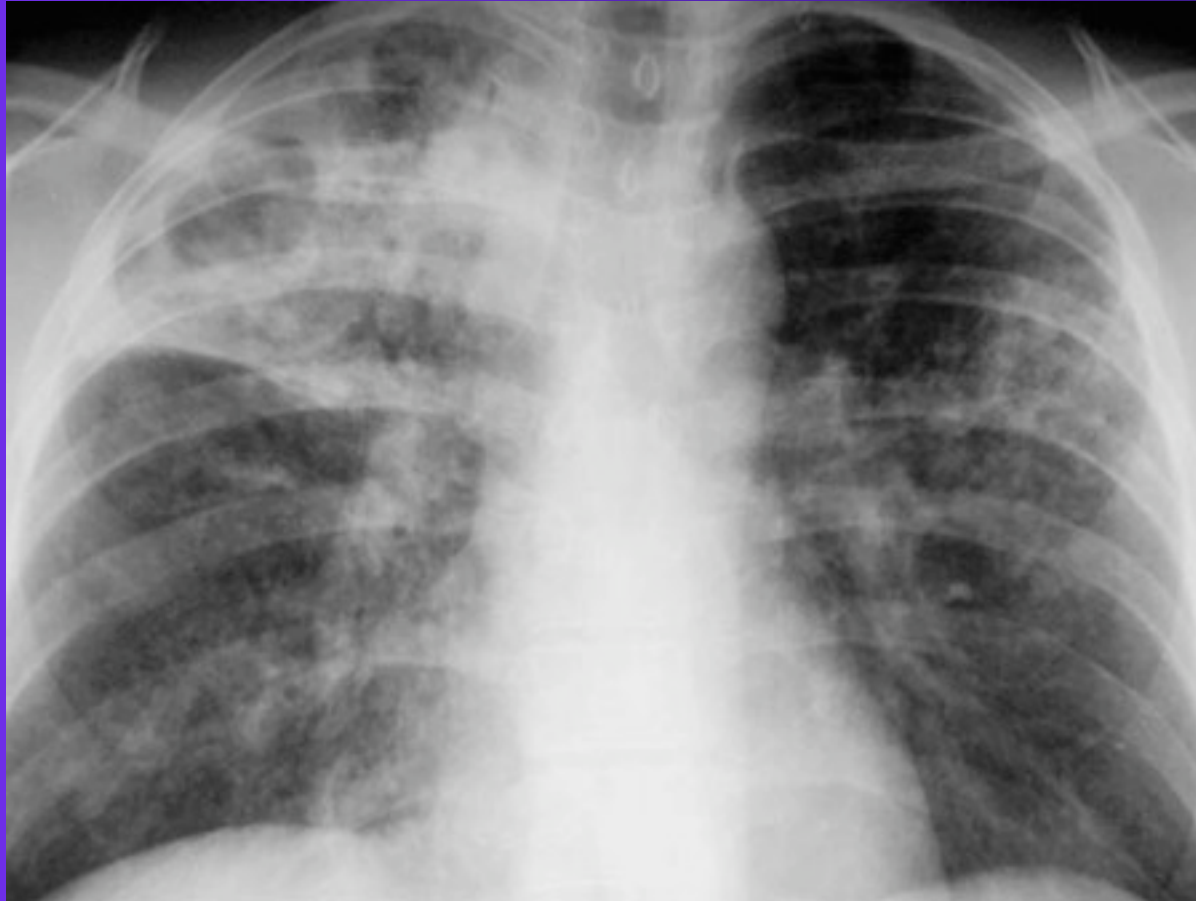
Post-Primary or Reactivation TB

- ◆ In order of frequency
 - Apico-posterior segments of upper lobes
 - Superior segments of lower lobes
 - Anterior segments of upper lobes
- ◆ Patchy or nodular shadows
- ◆ Loss of volume
- ◆ Fibrosis with or without cavitation

Gohn focus and lymphadenopathy



Reactivation TB



Miliary TB

